

## Case report:

### Girl with Trichobezoar- A case report

Dr Anoop Benny, Dr Cijo Alex, Dr K.S. Venkatarangan

Department of Psychiatry, SMVMCH, Puducherry

Sri Manakula Vinayagar Medical College and Hospital, Madhagadipet, Kalitheerthalkuppam, Puducherry (U.T.)-605107

**Corresponding author:** Dr Anoop Benny

Date of submission: 28 October 2014 ; Date of Publication: 10 December 2014

---

#### Abstract:

Trichobezoar is a bezoar (a mass trapped in gastrointestinal system) formed by Trichophagia (ingestion of hair) and is often associated with Trichotillomania (compulsive hair pulling). The condition has a varied onset and incidence among males and females. If untreated, it can lead to fatal complications. The following case report outlines the presentation of a 10 year old girl with complaints of abdominal pain and distension for a period of 10 days and the presence of a Trichobezoar on ultrasonography.

Keywords: Trichobezoar, Trichophagia, Trichotillomania, Rapunzel syndrome

---

#### Introduction:

A Trichobezoar is a bezoar (a mass trapped in gastrointestinal system) formed by the Trichophagia (ingestion of hair). Trichobezoars are often associated with Trichotillomania (compulsive hair pulling). The Rapunzel syndrome is a closely associated condition in which the hair ball is found in the stomach and its tail in the small or large intestine. It is named after the fairy tale girl Rapunzel who had long hair<sup>[1,2]</sup>.

#### Case Presentation

A 10 year old girl presented to the Paediatric OPD of SMVMCH with complaints of abdominal pain and distension for 10 days. General examination revealed pallor and lymphadenopathy along with a palpable mass in abdomen. Ultrasonography, endoscopy and contrast enhanced CT was done which reported gastric tricho/phytic bezoar with early features of Rapunzel's syndrome.

She underwent an elective surgery and the Trichobezoar measuring 8" X 8" X 5" and weighing 1200gm was removed by a mini

laparotomy under general anesthesia. The post-operative period was uneventful and patient reported gradual improvement of symptoms like increase in appetite and cessation of vomiting along with decreased abdominal pain over a week's period.

The Psychiatry department was informed and was referred for opinion on the 3<sup>rd</sup> post-operative day. The first appointment was used exclusively for rapport building considering the age of the patient. A detailed examination of the girl was done after the rapport was established. Hair loss pattern was not very obvious on her. After spending some time with her she admitted her habit of plucking hair and swallowing it occasionally when no one is around. The parents also reported that they have witnessed some instances in which she was found while plucking her hair though they considered it trivial. According to them it started soon after her younger brother was born.

This temporal relation warranted special attention and so she was re interviewed on another separate

occasion during which she complained that parents were expressing more love and affection towards her younger brother than her. She also reported mounting of tension before the plucking habit and relief once hair is plucked. After a detailed workup sibling rivalry was diagnosed.

The clinical psychologist saw the case and it was decided to put her on behavioral therapy. Now she is regularly attending our child guidance clinic with good improvement of symptoms.

**Discussion:**

Impulse control disorder is not very common in psychiatric consultation. It often presents in dermatology OPD, for hair loss, following which they are referred to psychiatry. The patients may also give history of biting and swallowing of hair leading to various symptoms of trichobezoar formation. Trichotillomania is an obsessive compulsive spectrum disorder which usually has a benign course if the onset is early in childhood. However, the disease has a prolonged course if the onset is late [1]. The female: male ratio reported in a survey was 5 to 10:1 [1]. The disorder is present in 0.6% of college students and the majority of patients are female, in an age group of 11- 16 years [2]. In a study conducted to determine emotional factors related to trichotillomania, it was concluded that emotional deprivation of maternal relationship in early years significantly contributed to the development of this particular impulse control disorder [3].

The patient may be brought or referred to the OPD with complaints of pulling of hair from the scalp, eyebrows, and eyelashes, sometimes symmetrically. Rarely, plucking of pubic and other bodily hair may also be noted [2]. Sometimes it may also be associated with other behaviours like nail biting, pica, biting inedible things etc. [1].

It is often observed that patients presenting with features of trichotillomania or the presence of a

trichobezoar, may already have other forms of psychiatric disorders like depression or anxiety disorder, substance abuse disorder or an eating disorder [2].

The widely followed treatment for Trichotillomania involves administration of SSRI (Selective Serotonin Receptor Inhibitors) like Fluoxetine and Paroxetine. Other types of treatment include behavioural therapy and CBT. Combined treatment using SSRI and HRT is considered the best modality of treatment [1,3,4].

**Conclusion:**

Trichotillomania is common among females with variable onset of age and course. International Classification of Diseases- 10 (ICD 10) codes Trichotillomania under F.63, Habit and Impulse disorders. If left undiagnosed and untreated it can lead to rare complications like Trichobezoar which can be fatal. It is also important to rule out any co-morbid conditions like Depression, Obsessive Compulsive Disorder, Pica, Mental Retardation or Child Abuse.

Figure 1: Showing Endoscopic view of trichobezoar

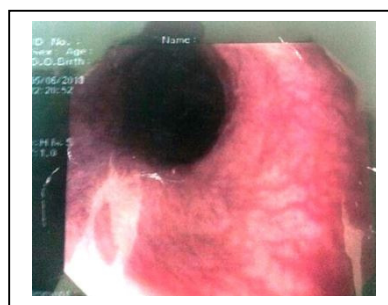
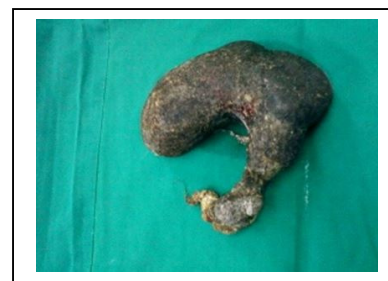

Figure 2: Showing the surgically removed specimen of trichobezoar



**References:**

1. Kumar KS, Kumar R. Habit reversal therapy- An effective treatment modality in adolescent trichotillomania: A case report. *J. Indian Assoc Child AdolescMent Health* 2012;8(4):105-12.
2. Minichiello WE, O'Sullivan RL, Osgood-Hynes D, Baer L. Trichotillomania: clinical aspects and treatment strategies. *Harv Rev Psychiatry*. 1994;1(6):336-44.
3. Fortune VM, Rafael AD. Trichotillomania in Children: A Review. *Am J Psychiatry* 1969;126:505-11.
4. R. R. Gorter, CMF Kneepkens, ECJ Mattens, DC Aronson, HA Heij. Management of trichobezoar: case report and literature review. *PediatrSurgInt* 2010;26:457-63.